

## REVIEW ARTICLE

# Healing Effect of Botox in Dental Office

<sup>1</sup>Rakesh Mittal, <sup>2</sup>M Singla, <sup>3</sup>H Aggarwal

## ABSTRACT

In this era of passion to look beautiful, various new technologies are emerging to enhance and improve the physical appearance of people. Botox is emerging as one such popular treatment to improve various facial anomalies. Minimally invasive treatment can be done by botox, which can expand our therapeutic options for the benefit of our patients. The aim of this article is to elaborate the healing aspect of this toxin, i.e., botox.

**Keywords:** Botulinum toxin, Bruxism, Gummy smile, Hypertrophy.

**How to cite this article:** Mittal R, Singla M, Aggarwal H. Healing Effect of Botox in Dental Office. J Oral Health Comm Dent 2017;11(1):13-18.

**Source of support:** Nil

**Conflict of interest:** None

## INTRODUCTION

Many of us think of botox primarily as a cosmetic treatment for lines and wrinkles on the face, whereas botox, a botulinum toxin derivative, has a long history of therapeutic uses.<sup>1</sup> Today, botox is the hottest name in the field of cosmetic and esthetic industry. Botox and dermal fillers are well known for their esthetic results in terms of smooth skin and replacing lost volume in face, especially the oral and perioral areas.<sup>2</sup> There are many innovative, minimally invasive uses for botox in dentistry. Most of the dentists are not aware of these other considerable therapeutic benefits of botox in dental treatment, which include temporomandibular joint disorders, bruxism, oromandibular dystonia (OMD), mandibular spasm, dental implant and surgery, gummy smile, and masseteric hypertrophy.<sup>3</sup>

## HISTORY

In the nineteenth century, Justinus Kerner described botulinum toxin as a "sausage poison" and "fatty poison"

(from Latin botulus meaning "sausage"),<sup>4</sup> because the bacterium that produces the toxin often caused poisoning by growing in improperly handled or improperly prepared meat products. The term "Botulism" was coined by Kerner, a physician, who first recognized the therapeutic use of botulinum toxin. In 1897, Emile van Ermengem isolated the botulin toxin from a bacterium, and named it *Clostridium botulinum*.<sup>5</sup> Snipe and Sommer<sup>6</sup> purified the toxin for the first time in 1928. In 1949, Burgen's<sup>7</sup> group experimentally discovered that botulinum toxin blocks neuromuscular transmission through decreased acetylcholine release. It can be absorbed from the eyes, mucous membranes, respiratory tract, or nonintact skin.<sup>4</sup> Botulinum toxin type I (Allergan's botox), has both therapeutic and cosmetic applications. Since 20 years, botox got approval from the Food and Drug Administration (FDA) for therapeutic treatments of eye muscle problems (in 1989), neck problems (in 2000), and excessive sweating (in 2004). At present, it is being investigated for treating other medical conditions.<sup>8</sup> Botox neurotoxin was accepted by the FDA in March 2010 for the treatment of increased muscle stiffness in the finger muscles, elbow, and wrist in people 18 years and older with upper limb spasticity.<sup>9</sup>

## DOSAGE AND MECHANISM OF ACTION

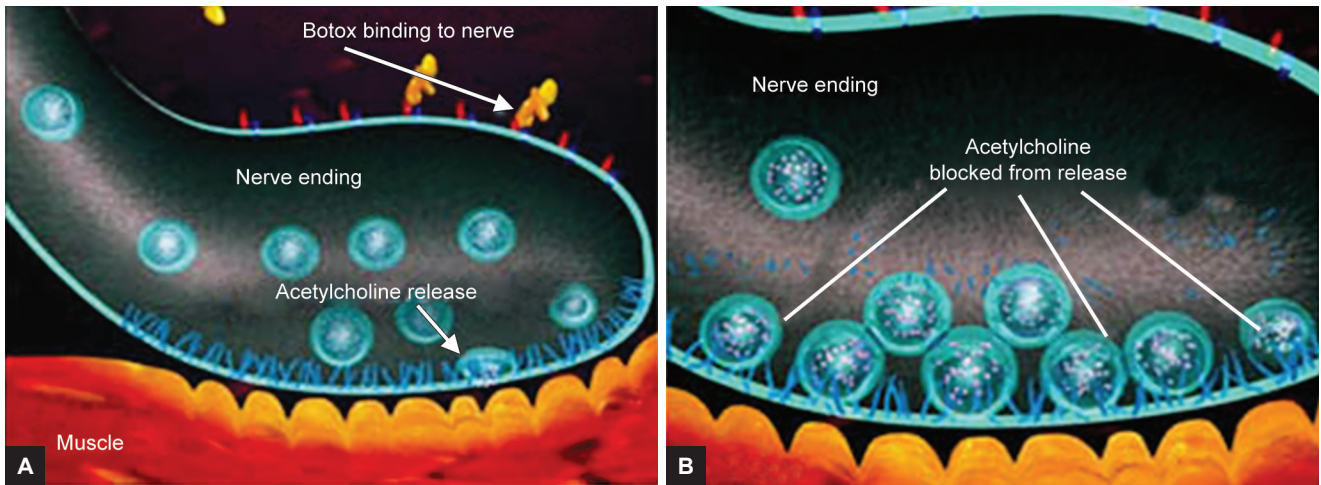
Commercially, two main types of botox are available: Botulinum toxin type I and botulinum toxin type II. Further, three forms of botulinum toxin type I, i.e., botox, Dysport, and Xeomin are available commercially for various cosmetic and medical procedures.

Botox can cause partial chemical denervation of the muscle, which results in localized reduction in muscle activity. Type I form of botulinum toxin inhibits the release of acetylcholine on cholinergic nerve endings of motor nerves,<sup>8</sup> as it avoids the vesicle where the acetylcholine is stored from binding to the membrane where the neurotransmitter can be released (Figs 1A and B). Botulinum toxin achieves this effect by its endopeptidase activity against SNARE proteins, which are 25-kD synaptosomal associated proteins that are required for the docking of the acetylcholine vesicle to the presynaptic membrane (Fig. 2).<sup>10</sup> Thus, botulinum toxin type I inhibits the release of acetylcholine by the neuron. This effectively weakens the muscle for a period of 3 to 4 months.<sup>11</sup> It was suggested that when botulinum toxin was used for the treatment of neuromuscular disorders, particularly

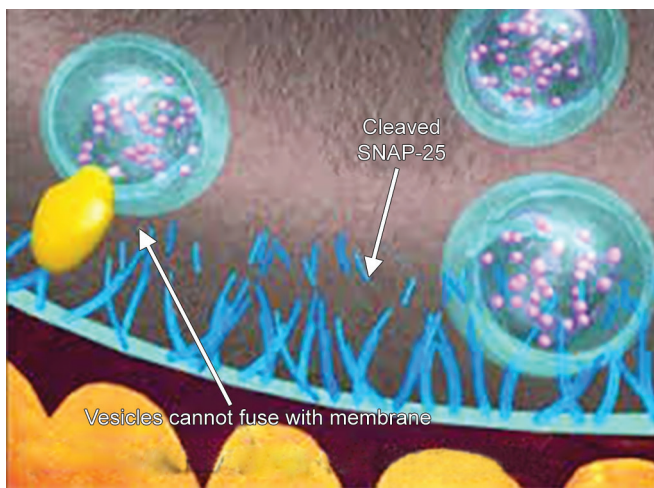
<sup>1</sup>Professor and Head, <sup>2</sup>Professor, <sup>3</sup>Postgraduate Student

<sup>1-3</sup>Department of Conservative Dentistry and Endodontics, Sudha Rustagi College of Dental Sciences & Research, Faridabad Haryana, India

**Corresponding Author:** Rakesh Mittal, Professor and Head Department of Conservative Dentistry and Endodontics, Sudha Rustagi College of Dental Sciences & Research, Faridabad Haryana, India, e-mail: guddurohtak@gmail.com



**Figs 1A and B:** (A) Botox binding to nerve ending; and (B) blocking release of acetylcholine



**Fig. 2:** Endopeptidase activity against SNARE proteins

focal dystonias and spastic conditions, patients reported a marked analgesic benefit. Initially, this benefit was believed to be due to the direct muscle relaxation effect of botulinum toxin; however, various observations have suggested that botulinum toxin may exert an independent action on peripheral nociceptors by blocking exocytosis of such neurotransmitters as substance P, glutamate, and calcitonin gene-related peptide. In addition, botulinum toxin does not cross the blood–brain barrier, and it is inactivated during its retrograde axonal transport; the effect is believed to be in the first-order sensory nerve and not more centrally.<sup>12</sup>

It can be used as an adjunct to oral medication or as a sole therapy. Botulinum toxin A is kept frozen (2–40°C) in a vial until it is mixed with 4 mL of 0.9% preservative-free normal saline solution, which makes it ready for use within 4 hours. Each vial of botox contains: 100 U of *Clostridium botulinum* type I neurotoxin complex, 0.9 mg of sodium chloride without a preservative in a sterile vacuum-dried form, and 0.5 mg of human albumin. The syringe preferred is a calibrated 1.0-mL tuberculin

syringe, and the needle selected for injection usually is between 26 and 30 gauge.<sup>13</sup>

Mouse unit is the expression of potency of botox. A unit of botox is defined as the LD50 for a colony of 20 gm Swiss-Webster mice,<sup>13</sup> extrapolated to the 70 kg human, and each 0.1 mL contain 2.5 U of botox. Botox is provided in small vials containing 500 U or 100 U in humans; lethal dose of botox is not prescribed. Although it has been estimated to be about 3000 U,<sup>14,15</sup> the maximum permissible dose of botox for dental applications at an injection session is about 80 to 100 U. It determines that 30 vials of botox will have to be injected before potentially destructive results. The cleaning of skin has to be done with a chlorhexidine/alcohol/betadine swab, before injecting botox into the joint and/or muscle and/or skin. Before injection, aspiration is recommended to avoid involuntary deposition of toxin into the facial arteries. Closed to immediate results can be achieved in one short appointment with the use of botulinum toxin A, but the results obtained are not permanent and stay for 6 months, with an average range of 4 to 8 months.<sup>16</sup> It has to be repeated 2 to 3 times a year depending upon the decrease in its effect. The therapeutic effects of botulinum toxin A start first appearing in 1 to 3 days, show peak level in 1 to 4 weeks, and start decreasing after 3 to 4 months.<sup>17</sup>

In a study, 3 to 4 weeks after a single injection of botulinum toxin A in mice, there is sprouting of new processes along the nerve axon, with formation of multiple synapses with the muscle and upregulation of the muscle nicotinic receptors. The original synaptic connection is restored after the neuronal sprouts undergo regression, with restoration of original neuromuscular junction.<sup>18,19</sup> Therefore, cost factor increases due to repeated administration of botulinum toxin injections 2 to 3 times a year. Injections are spaced out for a minimum of 3 months to minimize the risk of antibody formation to the protein, which would prevent botox from working the subsequent time.<sup>3</sup>

## APPLICATIONS OF BOTOX

Botox can be used in the treatment of various problems, which includes temporomandibular disorders (TMD), masseteric hypertrophy, hemifacial spasm, myofascial pain, bruxism, trismus, sialorrhea, retraining muscles during orthodontic therapy; in patients with a very strong musculature; training the patient to get used to new dentures, especially in patients with strong irregular muscle contractions and jaw line contouring by injecting into masseter muscle, thus weakening it and resulting in a more tapered jaw line.

### Temporomandibular Joint Disorders

Temporomandibular disorder is a term used to describe a number of diseases affecting masticatory function, which may include true pathology of the temporomandibular joint as well as masticatory muscle dysfunction.<sup>20,21</sup> The TMD is apparent with headache, neck pain, facial pain, periauricular pain, joint sounds, and/or decreased jaw excursion. The majority of TMD cases include a myogenic component, and muscular spasticity secondary to bruxism, external stressors, OMD, and psychomotor behaviors are common etiologic factors of TMD.<sup>22-24</sup>

Excessive biting forces causing TMD have conventionally been treated with occlusal adjustments, intraoral appliances, dental restoration, and/or surgery. These techniques are expensive, invasive, and irreversible for the majority of patients.

The techniques currently in use for conservative, esthetic restorations may not be able to stand with the parafunctional forces continually applied by some patients. Thus, these treatment options are not considered as ideal for all patients, so muscular relaxation with botulinum toxin A can be a viable alternative. When a muscle relaxant is used with the muscles of mastication, this clenching reflex can be reduced or eliminated.<sup>25</sup> Because a very small percentage of available force is required to masticate food, a slight relaxation of muscle function reduces bruxing and is usually insufficient to affect chewing and swallowing.<sup>26</sup>

### Temporomandibular Disorders Treatment Protocol

Treatment starts with a lower dose, because it is always possible to quantify up to a higher dose; if necessary, the pain of temporalis component is treated with bilateral injections of 7.5 U into the anterior vertical fibers of each temporalis muscle; 2.5 U dose can be given into the middle and posterior third of the temporalis muscles in more severe cases. Relief for pain for the tendon of temporalis is achieved with many injections of 2.5 U

equidistantly spaced in the temple area outside the orbital rim. The masseter component of pain is treated with 5 U injected into the belly of the masseter below an imaginary line joining the tragus of the ear and the corner of the mouth.<sup>14</sup>

Several case reports support the efficacy of botox treatment for TMD. Freund et al<sup>26</sup> conducted a large open-label trial with 46 patients suffering from TMD and found that 150 U injections of botox to the temporalis and masseter muscles significantly decreased pain and tenderness and improved function and mouth opening. Tan and Jankovic<sup>27</sup> conducted a long-term open-label trial on 18 patients with a history of severe bruxism. Botox injections can be given to the masseter muscle (mean dose: 61.7 U/side; range 25–100 U), yielding a total duration of therapeutic response of 19 weeks,<sup>27</sup> Lee et al<sup>28</sup> did a small open-label trial study to find out the effect of botox on pain due to TMD in six patients with limited mouth opening. All patients showed clinical remission of pain symptoms without any adverse effects during the 5 to 12 months follow-up period.

### Bruxism

Bruxism is a repetitive jaw-muscle activity characterized by clenching or grinding of the teeth and/or by bracing or thrusting of the mandible. It shows two distinct circadian manifestations: It can occur during wakefulness (indicated as awake bruxism) and during sleep (indicated as sleep bruxism). Botulinum neurotoxin has also shown promise in alleviating the symptomatology of bruxism. Excessive forces created by parafunctional clenching impede healing and reattachment of gum and bone in the mouth after trauma.<sup>29</sup> Botulinum toxin type I restricts the muscle contraction; this results in decreasing the clenching intensity. This will allow traumatized tissue to heal. Because parafunctional clenching can contribute toward the periodontal trauma, botulinum toxin type I can restrict clenching before and after periodontal surgery to improve the healing. Further, in this regard, the use of a splint is not recommended because the teeth should be functional during the healing phase, so botulinum toxin can also act as a pharmaceutical splint. One of the earliest reports on the use of botulinum toxin type I for bruxism was by Van Zandijcke and Marchau,<sup>30</sup> who described the successful treatment of a brain-injured patient with severe bruxism with 100 U of a botulinum toxin type I injection to the temporalis and masseter muscles.

### Oromandibular Dystonia

It is a movement disorder, i.e., characterized by involuntary spasms and muscle contractions. It is apparent as distorted function and oral positioning, resulting in



difficulty in eating, swallowing, and speaking. Although it is a neurologic disorder, it is included as a subset of TMD because of its involvement of the masticatory apparatus.<sup>31</sup> Most of the reported literature on OMD has been open-label studies, but all have reported improvement with botulinum toxin injections.<sup>32-36</sup> The largest study to date was a prospective open-label study conducted by Tan and Jankovic<sup>36</sup> that treated 162 patients with OMD over a 10-year period. Increase in the function for speaking and chewing was found in 67.9% of the patients, and clinical improvement was found to be  $16.4 \pm 7.1$  weeks.<sup>35</sup>

### Mandibular Spasm

It shows a condition in which closing musculature of mandible remains in spasm or semicontracted stage, which results in decrease in mouth opening. This type of muscular spasm causes restrictions in dental treatment and limits completion of the basic needs of oral hygiene, which is necessary to prevent many oral diseases. Botox treatment decreases the effect of spastic muscles or hyperfunctioning muscles that help in improving mouth opening and function. Botox treatment also effectively decreases tenderness and pain to palpation. Several case reports have been published, describing the effectiveness of botox in patients with hemimasticatory spasm, which includes studies conducted by Cersósimo et al,<sup>37</sup> Auger et al,<sup>38</sup> Kim et al,<sup>39</sup> and Kim et al,<sup>40</sup> where all the patients responded positively to botox injections.

### Dental Implant and Surgery

Implant patients will benefit from presurgical botox treatment. Overloading of the muscles of mastication can prevent or impede osseointegration of implants and/or fracture callus formation.<sup>41,42</sup> The muscular relaxation gained with botulinum toxin type I can be therapeutically beneficial for fracture healing in a more stable environment and also for dental implants, by allowing implants better unimpeded osseointegration.

Kayikçioğlu et al<sup>42</sup> did a small open-label study to find out the use of botulinum toxin type I as an adjunct to zygomatic fracture fixation surgery, in order to reduce the number of fixation sites and to prevent dislocation of the zygomatic bone. Zygomatic bone fractures of five male patients were injected with 100 U of botulinum toxin type I at the fractured site of masseter muscle; 12 to 48 hours after the injection, patients were then operated and electromyograph confirmation of muscle denervation was done. The temporary paralysis of the masseter muscles allowed for fewer miniplate and/or microplate insertions in all patients and resulted in no complications related to either the botulinum toxin injections or

surgical procedures. Kayikçioğlu group<sup>42</sup> also found similar benefits of adjunct botulinum toxin treatment for surgical reduction of mandibular and condylar bone fractures.

### Gummy Smile

The display of excessive gingival tissue in the maxilla upon smiling or the “gummy smile” is both an oral hygiene and esthetic issue with no simple remedy. Several surgical techniques have been reported in the literature for the correction of hyperfunctional upper lip elevator muscles, such as Rubinstein and Kostianovsky, Miskinyar, and Rees and LaTrenta techniques. However, routinely, they are not used to treat gummy smiles. Surgical corrections for skeletal vertical maxillary excess and gingivectomies for delayed passive dental eruption with excessive gingival display are corrected by the Lefort 1 maxillary osteotomies with impaction. Carefully titrated doses in small quantity can make these muscles proportionately weakened with botox, which will result in decreased exposure of the upper gums during smiling. Polo<sup>43</sup> carried out a study in five patients with excessive gingival display due to hyperactive upper lip elevator muscles who were treated with botox under electromyographic guidance. Patients received one 0.25 U injection per muscle bilaterally into the levator labii superioris, superioris labii alaeque nasi, and at the overlap areas of the levator labii superioris and zygomaticus minor muscles. All patients were satisfied with the obtained results. The effective increase in the upper lip length upon smiling averaged 124.2%, the duration of effect ranged from 3 to 6 months, and no adverse effects were reported or observed.

### Masseteric Hypertrophy

Patients who are chronic jaw clenchers frequently present with masseteric hypertrophy.<sup>44</sup> The size of these muscles is increased, and it is evident in the facial profile of patients, which is often altered, e.g., the jaw can appear misshapen and swollen. The commonly used treatment for this is the surgical resection, which may result in substantial contracture. In several small but well-documented clinical trials by Al-Ahmad and Al-Qudah,<sup>45</sup> Mandel and Tharakan,<sup>46</sup> and Rijdsdijk et al,<sup>47</sup> injection of small aliquots of botox into the masseter muscles resulted in a sustained reduction of masseter hyperactivity.

Besides these applications, botox can be used in hemifacial spasm, myofascial pain, trismus, sialorrhea, migraine cluster headache, retraining muscles during orthodontic therapy; in patients with a very strong musculature; training the patient to get used to new dentures, especially in patients with strong irregular

muscle contractions and jaw line contouring by injecting into masseter muscle, thus weakening it and resulting in a more tapered jaw line.

## CONTRAINDICATIONS

The relative contraindications include pregnancy, lactation, neuromuscular diseases (myasthenia gravis, Eaton-Lambert syndrome), motoneuron diseases, concurrent usage of aminoglycosides, and sensitivity to toxin.

## ADVERSE EFFECTS

Botulinum toxin in oromandibular disorders include facial nerve palsy, pain at the injection site, flu-like symptoms, nontargeted muscle weakness, dysphagia, and hematoma. These complications are generally transient and resolve within a couple of weeks.

## CONCLUSION

Undoubtedly, botox, a minimally invasive and attractive treatment, is the best option in comparison to surgical alternatives. However, there is much more still to be discovered to allow its routine use in dental clinics for various problems. There are still many conditions which require FDA approval to be treated by botulinum toxin. Therefore, minimally invasive botox will surely take dental profession one step ahead.

## REFERENCES

- Nayyar P, Kumar P, Nayyar PV, Singh A. BOTOX: broadening the horizon of dentistry. *J Clin Diagn Res* 2014 Dec;8(12):25-29.
- Peck S, Peck L, Kataja M. Some vertical linear measurement of lip position. *Am J Orthod Dentofac Orthop* 1992 Jun;101(6):515-524.
- Rao LB, Sangur R, Pradeep S. Application of botulinum toxin type A: an arsenal in dentistry. *Indian J Dent Res* 2011 May-Jun;22(3):440-445.
- Frank J, Erbguth. Historical notes on botulism, *Clostridium botulinum*, botulinum toxin, and the idea of the therapeutic use of the toxin. *Mov Disord* 2004 Mar;19(S8):S2-S6.
- Van Ermengem EP. Uebereinenneuenanaeroben Bacillus und seine Beziehungen zum Botulismus. *Zeitschrift Hyg Infektionskrankheiten* 1897;26(1):1-56.
- Snipe PT, Sommer H. Studies on botulinum toxin: 3. Acid precipitation of botulinum toxin. *J Infect Dis* 1928;43(2):152-160.
- Burgen ASV, Dickens F, Zatman LJ. The action of botulinum toxin on the neuro-muscular junction. *J Physiol* 1949 Aug;109(1-2):10-24.
- Meunier FA, Schiavo G, Molgo J. Botulinum neurotoxins: from paralysis to recovery of functional neuromuscular transmission. *J Physiol (Paris)* 2002;96(1-2):105-113.
- Brin MF. History of Onabotulinum toxin A. Botulinum toxin. *Procedures in cosmetic dermatology*. 3rd ed. 2013. p. 1-7.
- Aoki KR. Evidence for antinociceptive activity of botulinum toxin type A in pain management. *Headache* 2003 Jul-Aug;43(Suppl 1):S9-S15.
- Edwards M. Anal fissure. *Dumas Ltd*. [cited 2010 Aug 21]. 2006.
- Dressler D, Adib SF. Botulinum toxin: mechanisms of action. *Eur Neurol* 2005 Jan;53(1):3-9.
- Ko G. How Botox works for the treatment of chronic pain. Canada: Canadian Centre for Integrative Medicine; 2009. [cited Aug 2009]. Available from: [http://www.drkoprp.com/pdfs/botox Info.pdf](http://www.drkoprp.com/pdfs/botox%20Info.pdf).
- Katz H. Botulinum toxin in dentistry – the new paradigm for masticatory muscle hypertonicity. *Singapore Dent J* 2005 Dec;27(1):7-12.
- Katz H. Can Botulinum toxin A (BOTOX) save your teeth and enhance your smile? 2004. [cited 2009]. Available from: <http://sci.tech-archive.net/Archive/sci.med.dentistry/2004-06/0484.html>.
- Grover S, Malik V, Kaushik A, Diwakar R, Yadav P. A Future perspective of Botox in dentofacial region. *J Pharm Biomed Sci* 2014 Jun;4(6):525-531.
- Clark GT, Stiles A, Lockerman LZ, Gross SG. Botulinum toxin in orofacial pain disorders. *Dent Clin North Am* 2007 Jan;51(1):245-261.
- Patel D, Mehta F, Trivedi R, Thakkar S, Suthar J. Botulinum toxin and gummy smile – a review. *IOSR-JDMS* 2013 Jan-Feb;4(1):1-5.
- Jankovic, J.; Comella, CL.; Brin, MF, editors. *Dystonia: etiology, clinical features, and treatment*. Philadelphia, PA: Lippincott Williams & Wilkins; 2004. p. 93-112.
- Bentsianov B, Francis A, Blitzer A. Botulinum toxin treatment of temporomandibular disorders, masseteric hypertrophy, and cosmetic masseter reduction. *Oper Tech Otolaryngol Head Neck Surg* 2004 Jun;15(2):110-113.
- Olivio SA, Bravo J, Magee DJ, Thie NM, Major PW, Flores-Mir C. The association between head and cervical posture and temporomandibular disorders: a systematic review. *J Orofac Pain* 2006 Winter;20(1):9-23.
- Schwartz, M.; Freund, B. *Botulinum toxin a therapy for temporomandibular disorders*. Philadelphia, PA: Lippincott Williams & Wilkins; 2002.
- Schwartz M, Freund B. Treatment of temporomandibular disorders with botulinum toxin. *Clin J Pain* 2002 Nov-Dec;18 (Suppl 6):S198-S203.
- Castenada, R. Occlusion. In: Kaplan A, Assael L, editors. *Temporomandibular disorders*. Philadelphia, PA: Saunders; 1992.
- Gobel H, Heinze A, Heinze-Kuhn K. Botulinum toxin A is effective in cases of oromandibular dysfunction even if previous bite splint therapy has proved unsuccessful. *Cephalalgia* 2001 May;21(4):514-515.
- Freund B, Schwartz M, Symington JM. The use of botulinum toxin for the treatment of temporomandibular disorders: preliminary findings. *J Oral Maxillofac Surg* 1999 Aug;57(8):916-921.
- Tan EK, Jankovic J. Treating severe bruxism with botulinum toxin. *Am Dent Assoc* 2000 Feb;131(2):211-216.
- Lee KM, Chow J, Hui E, Li W. Botulinum toxin type A injection for the management of myofascial temporomandibular pain disorder. *Asian J Oral Maxillofac Surg* 2005 Jun;17(2):100-103.
- Glaros A, Tabacchi K, Glass EG. Effect of parafunctional clenching on TMD pain and hearing loss. *J Orofac Pain* 1998 Spring;12(2):145-152.

30. Van Zandijcke M, Marchau MM. Treatment of bruxism with botulinum toxin injections. *J Neurol Neurosurg Psychiatr* 1990 Jun;53(6):530.
31. Blitzer A, Brin MF, Greene PE, Fahn S. Botulinum toxin injection for the treatment of oromandibular dystonia. *Ann Otol Rhinol Laryngol* 1989 Feb;98(2):93-97.
32. Brin MF, Fahn S, Moskowitz C, Friedman A, Shale HM, Greene PE, Blitzer A, List T, Lange D, Lovelace RE, et al. Localized injections of botulinum toxin for the treatment of focal dystonia and hemifacial spasm. *Mov Disord* 1987;2(4):237-254.
33. Hermanowicz N, Truong DD. Treatment of oromandibular dystonia with botulinum toxin. *Laryngoscope* 1991 Nov;101(11):1216-1218.
34. Jankovic J, Orman J. Botulinum toxin for cranial-cervical dystonia: a double-blind, placebo-controlled study. *Neurology* 1987 Apr;37(4):616-623.
35. Laskawi R, Rohrbach S. Oromandibular dystonia. Clinical forms, diagnosis and examples of therapy with botulinum toxin. *Laryngorhinootologie* 2001 Dec;80(12):708-713.
36. Tan EK, Jankovic J. Botulinum toxin A in patients with oromandibular dystonia: long-term follow-up. *Neurology* 1999 Dec;53(9):2102-2107.
37. Cersósimo MG, Bertoti A, Roca CU, Micheli F. Botulinum toxin in case of hemimasticatory spasm with severe worsening during pregnancy. *Clin Neuropharmacol* 2004 Jan-Feb;27(1):6-8.
38. Auger RG, Litchy WJ, Cascino TL, Ahlskog JE. Hemimasticatory spasm: clinical and electrophysiologic observations. *Neurology* 1992 Dec;42(12):2263-2266.
39. Kim HJ, Jeon BS, Lee KW. Hemimasticatory spasm associated with localized scleroderma and facial hemiatrophy. *Arch Neurol* 2000 Apr;57(4):576-580.
40. Kim YJ, Lee KS, Na JH, Kim BS, Ko YJ. A case of hemimasticatory spasm. *J Korean Neurol Assoc* 1994;12:175-178.
41. Nishimura K, Itoh T, Takaki K, Hosokawa R, Naito T, Yokota M. Periodontal parameters of osseointegrated dental implants: a four-year controlled follow-up study. *Clin Oral Implants Res* 1997 Aug;8(4):272-278.
42. Kayikçioğlu A, Erk Y, Mavif E, Vargel I, Özgür F. Botulinum toxin in the treatment of zygomatic fractures. *Plast Reconstr Surg* 2003 Jan;111(1):341-346.
43. Polo M. Botulinums type A (Botox) for the neuromuscular correction of excessive gingival display on smiling (gummy smile). *Am J Orthod Dentofacial Orthop* 2008 Feb;133(2):195-203.
44. Hui AC. Botulinum toxin for treatment of masseteric hypertrophy. *J Neurol* 2002 Mar;249(3):345.
45. Al-Ahmad HT, Al-Qudah MA. The treatment of masseter hypertrophy with botulinum toxin type A. *Saudi Med J* 2006 Mar;27(3):397-400.
46. Mandel L, Tharakan M. Treatment of unilateral masseteric hypertrophy with Botulinum toxin: case report. *J Oral Maxillofac Surg* 1999 Aug;57(8):1017-1019.
47. Rijdsdijk BA, van ES RJ, Zonneveld FW, Steenks MH, Koole R. Botulinum toxin type A treatment of cosmetically disturbing meseteric hypertrophy. *Ned Tijdschr Geneesk* 1998 Mar;142(10):529-532.