

# Lip Prints - Can it Aid in Individual Identification

Amith HV<sup>1</sup>, Anil V Ankola<sup>2</sup>, Nagesh L<sup>3</sup>

## ABSTRACT

**Objectives:** To compare the Lip Print Patterns of males and females, and to find out quadrant wise and sex wise predilection of lip print patterns.

**Materials and Methods:** A total of 200 dental students who satisfied the eligibility criteria were selected. Lip impressions of all these subjects were recorded. Suzuki's classification of Lip Prints was used and the results were analyzed.

**Results:** Type II pattern was dominant in males in the Third and Fourth quadrants. Type III pattern did not occur in Third and Fourth quadrants at all. It has occurred in First/ Second quadrant exclusively in males. The results were found to be statistically significant.

**Conclusions:** With these results it can be concluded that Lip Prints are characteristic of an individual and behold a potential in individual identification like the Finger Prints. Further longitudinal investigations with larger sample size should be carried out to know more about this science.

**Keywords:** Lip prints; Individual identification; Cheiloscopy.

---

<sup>1</sup>Reader  
Department of Public Health Dentistry,  
AB Shetty Memorial Institute of Dental Sciences,  
Nitte University,  
Deralakatte, Mangalore-575018.  
Karnataka, India

<sup>2</sup>Professor and Head,  
Department of Public Health Dentistry,  
KLEVK Institute of Dental Sciences,  
Belgaum, Karnataka  
India

<sup>3</sup>Professor and Head,  
Department of Public Health Dentistry,  
Bapuji Dental college,  
Davangere, Karnataka  
India

## INTRODUCTION

In India, as well as all over the world today, crimes of different nature are on the rise. Both criminals and educated elite of the society are making use of sophisticated technical measures while committing their crimes, to put the forensic scientist, police and the public off the scene. Hence the role of crime scene detectives has become challenging than ever in this civilized modern world.

As the crime scene investigation procedures are becoming more methodical and scientific, criminals are evolving novel techniques to beat them. Finger-prints, post-mortem reports and of late, the DNA finger printing methods are being used to extract conclusive evidence in the court of law. Forensic Odontology plays an important role in the identification of human remains. History reveals the use of Forensic Odontology since 49 A.D (1). The underlying tenet for dental identification is that combinations of dental characteristics are never the same in any two given individuals. Based on the quality and quantity of concordant points available different 'levels' or 'categories' of identification can be assigned to cases that indicate their proximity to a positive identification (2).

The biological systems of furrows on the red part of human lips were first noted by anthropologists. R. Fisher was the first to describe it in 1902 (3). Cheiloscopy is a forensic investigation technique that deals with identification of humans based on Lip traces (3). Labial mucosa a part of oral mucosa is not smooth like buccal mucosa or soft palate. It has many elevations and depressions forming a characteristic pattern called "Lip Prints". The examination of these Lip Prints is called "Cheiloscopy" (4). Uniqueness is the feature of Lip prints, which substantiates its usefulness in various situations. Cheiloscopy can be used as an invaluable tool in individual identification. There have been instances where "Cheiloscopy" has landed criminals behind bars, substantiating its acceptance in the court of law (5). In case when the lines are not clear, individual identification of a human being is possible by examining the substance which constitutes the trace e.g. saliva. The potential for DNA typing from the lip print is evidentially here. A lip print at the scene of a crime can be a basis for conclusions as to the character of the event, the number of the people involved, sexes, cosmetics used, habits, occupational traits and the pathological changes of lips themselves (3). Cheiloscopy can open new horizons in individual identification, be it crime scene or mass disaster.

---

## Contact Author

Dr. Amith H.V  
amith\_hv@yahoo.co.in

J Oral Health Comm Dent 2011;5(3)113-118

Dental identification, fingerprint and DNA comparisons are probably the most common techniques used in this context, allowing fast and secure identification processes. However, since they cannot always be used, sometimes it is necessary to apply different and less known techniques. Where identification is concerned, the mucosal area of the lip holds the most interest. This area, also called Klein's zone, is covered with wrinkles and grooves that forms a characteristic pattern—the lip print (6). The importance of Cheiloscopy is linked to the fact that lip prints are unique to one person, except in monozygotic twins (1, 6, 7). Like fingerprints and palatal rugae, lip grooves are permanent and unchangeable. It is possible to identify lip patterns as early as the sixth week of intra uterine life (6). From that moment on, lip groove patterns rarely change, resisting many afflictions, such as herpetic lesions. Lip Prints are considered to be the most important forms of transfer evidence and are analogues to finger prints (4).

The presence of lipstick stains on a suspect's clothing can be considered, as an indirect evidence of a relationship between the suspect and the cosmetic using victim. Lip Prints can be used to verify the presence or absence of a person from the crime, provided there has been consumption of beverage, drinks, usage of cloth, tissue/napkin etc, at the crime scene. Smears can also be found in other places such as cups, spoons or cigarette butts (8). The middle 10 mm wide part of the lower lip is almost always visible in traces. The determination of the pattern depends on the numerical superiority of properties of the lines on the fragment.

Though classification systems of lip prints has been presented, literature reveals, that very rarely Forensic odontologists have concentrated on this method of individual identification. Since lips form the border of the oral cavity, may be the reason, why they have not been extensively studied. Although lip print identification has been utilized in court in isolated cases more research needs to be conducted in this field

with regard to confirmation of uniqueness, and the collection and interpretation of evidence. There is a need for Lip print identification to be acceptable in the court as scientifically based evidence.

Previous studies have not conclusively differentiated lip print patterns between genders. Due to lack of studies in this regard, an investigation was opened to find out the predominance of Lip Print patterns between males and females. The aim of the present study was to evaluate the use of Cheiloscopy in identification of individuals. The objectives were to check the feasibility of recording lip prints using lipstick and cellophane tape, to compare the Lip print Patterns of males and females and to find out quadrant wise and sex wise predilection of lip print patterns.

#### **METHODOLOGY**

The present study was conducted to assess the quadrant wise and genderwise predilection of Lip print patterns among males and females.

A total of 200 dental students of the KLES Institute of Dental Sciences, Belgaum volunteering to participate in the study and willing to provide informed consent were included in the study.

All the subjects were in the age range of 19-25 years consisting of 100 male and 100 female students. Ethical clearance was obtained from the institutional Ethical Committee.

#### **Inclusion criteria**

- Subjects willing to participate in the study and providing informed consent.
- Subjects free from any active or passive lesions on their lips.

#### **Exclusion Criteria**

- Gross deformities of lips like cleft lip, ulcers, traumatic injuries on lips.
- Known allergy to the lip stick used.

#### **Materials used**

- Dark shaded lip stick
- Ear buds
- Cellophane tape

- White paper (proforma for recording lip prints)
- Scissors
- Magnifying lens
- Sanitary tissues (to wipe the lip stick)

#### **Period of study**

Lip prints were collected from the subjects after obtaining their informed consent in the month of October 2005.

The survey was carried out using a self-designed format. Lip prints were recorded on a white paper, and each lip print was assigned a serial number. The name and general information of the subjects like age, sex, and address were recorded on the consent form.

Ear buds, Cellophane tape, White paper, Magnifying lens and Scissors were used to record lip prints. On one end of an ear bud, lip stick enough for upper lip was taken. Lip stick was applied in a single motion on the upper lip. Similarly the other end of the ear bud was used to apply lipstick to the lower lip after which the ear bud was discarded maintaining strict aseptic conditions. Lip impressions were made on the sticking side of a cellophane tape, applying uniform pressure and the tape was taken out in a single jerk motion. It was then stuck on to a white paper which served as a permanent record. After acquiring the patterns of the subjects, each of them was assigned a definite number and studied carefully with a magnifying lens to analyze quadrant-wise, denoting the type according to Suzuki's classification (1970) of Lip prints (Fig. 1). The determination of the pattern was based on numerical superiority of properties of the lines in the study area.

#### **STATISTICAL ANALYSIS**

All the data were entered in Microsoft excel and analyzed using SPSS package (version 12).

All the data were presented as frequency and percentages. Chi square test was used to analyze and compare the lip print patterns. The level of significance was set at  $p < 0.05$ .

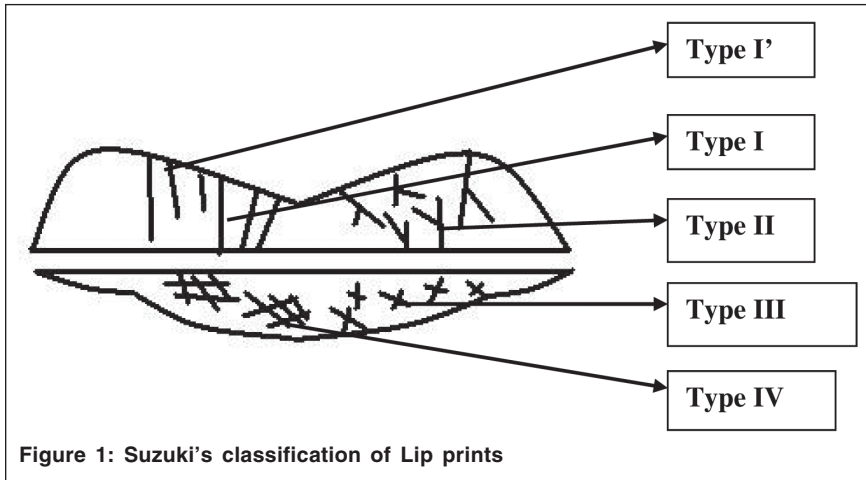


Figure 1: Suzuki's classification of Lip prints

**Suzuki's classification:**

- **Type I:** Vertical, complete (end-to-end) longitudinal fissures.
- **Type I'** (one - dash): Incomplete vertical longitudinal fissures.
- **Type II:** Branching, Y-shaped pattern.
- **Type III:** Criss-cross pattern.
- **Type IV:** Reticular, typical chequered pattern, fence like.

the quadrant wise and gender wise predilection of Lip print patterns. Lip print impressions were obtained from both males and females and were classified by

Suzuki's classification. The distribution of lip print types in males and females in each quadrant were compared.

This table depicts the overall results of the present study. The distribution of various types of lip prints in all the four quadrants of both males and females have been summarized here.

**First quadrant (Figure 2)**

Type I pattern was seen in 16% of males, compared to 42% of females. Type I' pattern was observed in 45% of males and 36% of females. Type II pattern was observed in 25% of males and 11% of females. Type III pattern was noted in 2% of males. This pattern did not occur in females in this quadrant. Type IV pattern was seen in 12% of males and 11% of

**RESULTS**

The present study was conducted to assess

**Table 1: Distribution of Lip print patterns**

	Male	Female
<b>Type I</b>		
First quadrant	16	40
Second quadrant	10	38
Third quadrant	10	53
Fourth quadrant	18	53
<b>Type I'</b>		
First quadrant	45	36
Second quadrant	42	37
Third quadrant	27	18
Fourth quadrant	27	16
<b>Type II</b>		
First quadrant	25	12
Second quadrant	27	11
Third quadrant	61	24
Fourth quadrant	52	26
<b>Type III</b>		
First quadrant	02	Nil
Second quadrant	04	Nil
Third quadrant	Nil	Nil
Fourth quadrant	Nil	Nil
<b>Type IV</b>		
First quadrant	12	11
Second quadrant	18	14
Third quadrant	02	04
Fourth quadrant	02	07

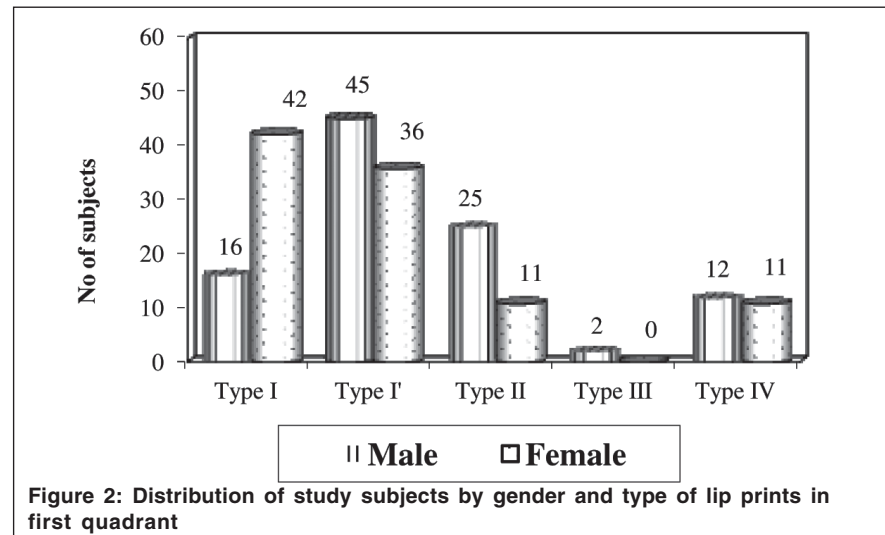


Figure 2: Distribution of study subjects by gender and type of lip prints in first quadrant

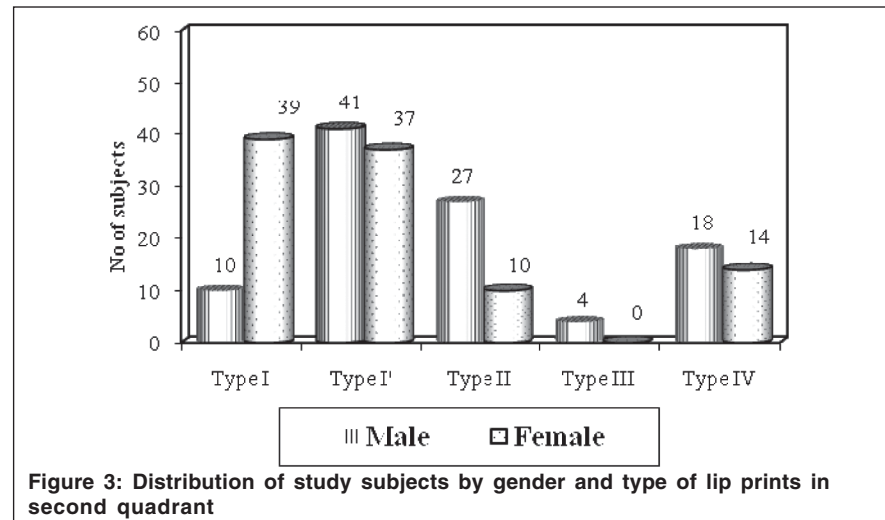
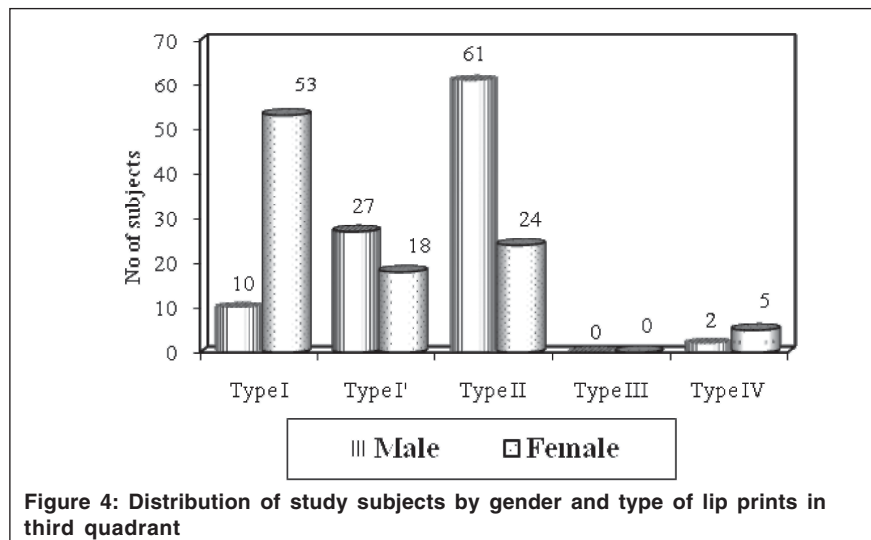


Figure 3: Distribution of study subjects by gender and type of lip prints in second quadrant



**Figure 4: Distribution of study subjects by gender and type of lip prints in third quadrant**

females. The distribution of the Lip print types was seen to be statistically significant (Chi-square= 20.14 and  $p < 0.01$ ).

**Second quadrant (Figure 3)**

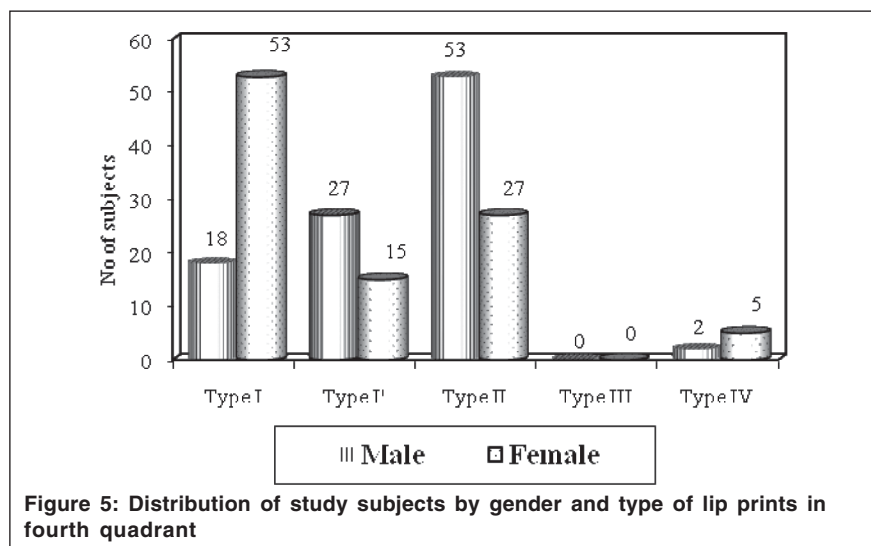
Type I pattern was seen in 10% of males, compared to 39% of females. Type I' pattern was observed in 41% of males and 37% of females. Type II pattern was observed in 27% of males and 10% of females. Type III pattern was noted in 4% of males. This pattern did not occur in females in this quadrant. Type IV pattern was seen in 18% of males and 14% of females. The distribution of the Lip print types was seen to be statistically significant (Chi-square= 29.67 and  $p < 0.01$ ).

**Third quadrant (Figure 4)**

Type I pattern was seen in 10% of males, compared to 53% of females. Type I' pattern was observed in 27% of males and 18% of females. Type II pattern was observed in 61% of males and 24% of females. Type III pattern did not occur in males nor females in this quadrant. Type IV pattern was seen in 2% of males and 5% of females. The distribution of the Lip print types was seen to be statistically significant (Chi-square= 48.54 and  $p < 0.01$ ).

**Fourth quadrant (Figure 5)**

Type I pattern was seen in 18% of males, compared to 43% of females. Type I' pattern was observed in 27% of males and



**Figure 5: Distribution of study subjects by gender and type of lip prints in fourth quadrant**

15% of females. Type II pattern was observed in 53% of males and 27% of females. Type III pattern did not occur in males nor females in this quadrant. Type IV pattern was seen in 2% of males and 5% of females. The distribution of the Lip print types was seen to be statistically significant (Chi-square= 30.41 and  $p < 0.01$ ).

All quadrants having the same type of Lip print was found in 6% of males and 13% of females. Three quadrants with the same type of lip print were observed in 63% of males and 50% of females. Two quadrants having the same type of Lip prints were seen in 26% of males and 28% of females. All quadrants having different type of lip prints was noted in 5% of males and 9% of females.

**DISCUSSION**

Crimes challenge the society in detection, diagnosis and identification of criminals. Establishing a person's identity can be a very difficult process. The most commonly used techniques like the fingerprint, DNA and Dental identification cannot always be used. Hence the search for various other means of personal identification continues. It is known that due to their special features, both lip grooves and palatal rugae can be used successfully in human identification (6,9).

Research into lip print identification has been performed for the last 50 years, resulting in the importance of this technique being recognized and accepted in many countries. Many studies have characterized lip prints in order to ascertain their unique features and characteristics (10), with lip print types, forensic applications of the technique (7), and method of acquiring lip impressions at the crime scene (10). Studies have shown though lips grow with age (11), the lip print invariably remains the same. Post mortem study of lip prints suggests that clear and identifiable lip prints could be obtained if taken less than 24 hours after death (12).

In the present study Type I and I' patterns were most commonly seen in the first quadrant, against Type I and II, as reported

by Vahanwala and Parekh (1). Type I pattern was found to be dominant in females in third and fourth quadrants in accordance with the study by Vahanwala and Parekh (1). Type II was dominant in males in the Third and Fourth quadrants as against in second quadrant reported by Vahanwala and Parekh (1). Type III pattern did not occur in Third and Fourth quadrants at all. It has occurred in First/ Second quadrant exclusively in males, similar to the one suggested by Vahanwala and Parekh (1). All four Quadrants having the same type of patterns was predominantly seen in female subjects. Two quadrants having the same predominant lip print pattern was the most commonly occurring trend. Similar conclusions were drawn by Vahanwala and Parekh (1). All quadrants having different types of lip prints were found more in females compared to males in contrast to the results of Vahanwala and Parekh (1). Shivapathasundharam B, Ajay Prakash P and Sivakumar G (4) have conducted a study of lip prints in 2001, in which Tsushihashi's classification of Lip prints has been used. They have assessed the middle part of the lower lip (10mm wide), as this fragment is almost always visible in any trace. They concluded that intersecting pattern was predominantly seen (41.33%) and reticular pattern was least commonly seen (10.71%).

Hence Lip prints can be used to verify the presence or absence of a person from the crime, provided there has been consumption of beverage, drinks, usage of cloth, tissue/ napkin etc. at the crime scene (1). Smears can also be found in other places, such as glasses, cups, spoons or cigarette butts, therefore indicating some kind of relationship between a suspect and the crime scene (7). Lip marks can be observed on ordinary drinking glass by an individual, even without lipstick being applied. Hence taking lip prints of all the suspected individuals and comparing with any such item found at the scene of crime could give conclusive evidence on the presence/ absence of a person and should be admissible even in the court of law. The other investigations become easier, once

the presence/ absence of a suspect from the scene are confirmed.

### UNIQUENESS OF LIP PRINTS

Studies done previously have shown that Lip prints are unique to individuals and remain unchanged throughout life. Identifiable lip prints can be obtained up to 30 days after being produced (12). Lipstick smears are frequently encountered in forensic science laboratories as one important form of transfer evidence. The presence of lipstick stains on a suspect's clothing can be considered indirect evidence of a relationship between the suspect and the cosmetic-using victim. Smears can also be found in other places, such as glasses, cups, spoons or cigarette butts, therefore indicating some kind of relationship between a suspect and the crime scene. Some classic works have contributed to the study of lip prints as a means of personal identification (12).

Until more scientific investigation regarding the reliability of lip prints has been done it is highly doubtful, that this technique will be admissible in the court of law for identification purposes. Cheiloscropy is still an inexact science and more studies need to be done to confirm its validity.

### LIMITATIONS OF CHEILOSCOPY

The lip print is produced by a substantially mobile portion of the lip. This fact alone explains the reason why the same person can produce different lip prints, according to the pressure, direction and method used in taking the print. If lipstick is used, the amount can also affect the print. Smudging of lip prints is one of the major limitations of using lip sticks as in the presents study. Manual register of the overlay is another problem, due to the possibility of some subjectivity. Another factor to be considered is the existence of some pathological conditions (lymphangiomas, congenital lip fistula, lip sclerodermi, Merkelson–Rosenthal syndrome, syphilis, lip cheilitis, among others), which can invalidate the cheiloscopic study. One must also consider the possibility of post-mortem changes of lip prints from cadavers with various causes of death. Utsuno et al have studied these

changes and concluded that a satisfactory identification rate was achieved. However, this study was carried out under a laboratory environment and what happens to lip prints obtained from cadavers exposed to the natural environment is still not known. It should also be pointed out that only in very limited circumstances, is there antemortem data referring to lip prints, which obviously impairs a comparative study where necroi-identification is concerned. The main feature for dental identification is the existence of antemortem data, which cannot be expected in cheiloscropy. Therefore, the only use of cheiloscropy will be to relate lip prints to the lips that produced them.

### CONCLUSION

When individual identification is concerned, Lip prints can be used as an aid, where other commonly used identification sources are not available. Even if the entire lip trace is not available, the cosmetic or the DNA traces are an immense treasure for identification.

The conclusions from the present study are as follows:

- Cellophane tape and lip stick can be easily used to retrieve lip prints
- Lip prints have a quadrant-wise predilection
- The distribution of lip prints is unique for males and females

With these results it is clearly evident that Lip prints are characteristic of an individual and behold a potential in individual identification, much like the Finger Prints. Also, studies have shown that Lip prints are consistent for an individual for life time(1,3). The existing classification does not take into account all the various types of patterns occurring on the lips. Perhaps a more comprehensive classification of the lip print patterns is the need of the hour. It will be better if a method is standardized to analyze the lip prints, may be with the help of some software programs, in the wake of recent technological advancements in Forensic Investigations. Exploration of literature reveals that very few have

ventured this area, and that there are many untreaded paths, which have to be covered. Hope this study invites at least a few curious minds to think over the wonderful science of Cheiloscopy. However further longitudinal studies with larger sample sizes are recommended to substantiate the results.

## REFERENCES

1. Vahanwala SP, Parekh BK. Study of lip prints as an aid to forensic Methodology. *JFMT* 2000;**17**(1):12-18.
2. Acharya AB, Taylor JA. Are a minimum number of concordant matches needed to establish identity in forensic odontology?. *J Forensic Odontostomatol* 2003;**21**:6-13.
3. Kasprzak J. Cheiloscopy, Encyclopedia of forensic sciences, Vol 1. New York: Academic press; 2000.
4. Sivapathasundharam B, Prakash PA, Sivakumar G. Lip prints (Cheiloscopy). *Indian J Dent Res* 2001;**12**(4):234-37.
5. Available on: ebend@netlabs.net [accessed on 12.09.11]
6. Caldas IM, Magalhaes T, Afonso A. Establishing identity using cheiloscopy and palatoscopy. *Forensic Sci Int*; accepted 21 April 2006. Article in Press. Available from URL: <http://www.sciencedirect.com/sdarticle.pdf>
7. Suzuki K, Tsuchihashi Y. New attempt of personal identification by means of lip print. *J Indian Den Assoc* 1970;**(1)**:08-10.
8. Segui MA, Feucht MM, Ponce AC, Pascual FAV. Persistent lipsticks and their lip prints:new hidden evidence at the crime scene. *Forensic Sci Int* 2000;**112**(1):41-47.
9. Limson KS, Julian R. Computerized recording of the palatal rugae pattern and an evaluation of its application in forensic identification. *J Forensic Odontostomatol* 2004;**22**(1):1-4.
10. Endris R, Poetsch-Schneider L. Value of human lip lines and nail striations in identification. *Arch Kriminol* 1985;**175**(1-2):13-20.
11. Hashim HA, Sarhan OA, Bukhary MT, Feteih R. Vertical and horizontal linear growth of the maxillary and mandibular lips: a longitudinal study. *J Clin Pediatr Dent* 1997;**21**(2):125-29.
12. Utsuno H, Kanoh T, Tadokoro O, Inoue K. Preliminary study of post mortem identification using lip prints. *Forensic Sci Int* 2005;**149**(2-3):129-32.